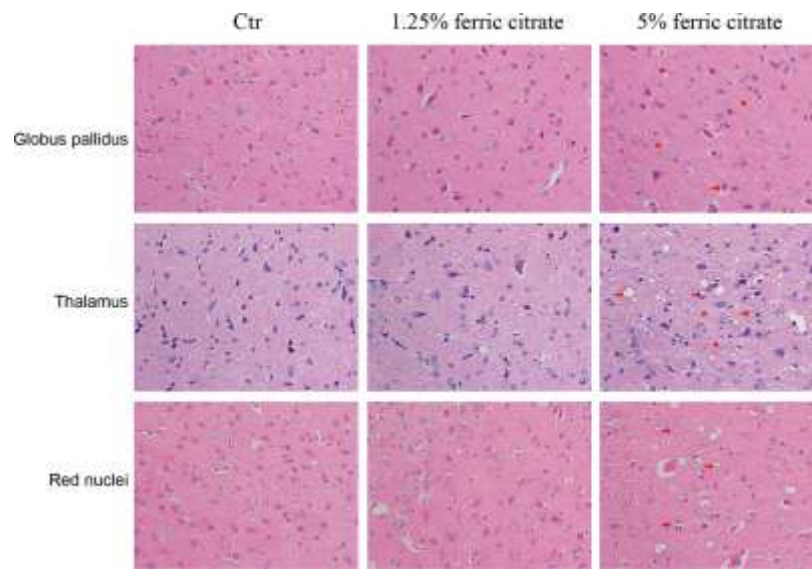


## SUPPLEMENTARY FIGURE



**Supplementary Figure 1. Representative images of H&E staining display the histopathological damage in globus pallidus, thalamic and red nuclei of the brain induced by ferric citrate supplementation. Red Stars show white matter edema, red arrows show display nerve cell swelling.**